

ADVANCES IN RADIATION THERAPY FOR PROSTATE CANCER

Nitya Patanjali¹ and Scott Williams²

1. Radiation Oncology, Sydney Cancer Centre, Royal Prince Alfred Hospital, Sydney.

2. Radiation Oncology, Peter MacCallum Cancer Centre, Melbourne, Victoria.

Email: Nitya.Patanjali@sswahs.nsw.gov.au

Abstract

The last decade has seen several new treatment technologies being incorporated into the radiation treatment of localised prostate cancer. More established treatment modalities, such as external beam radiation therapy, are being constantly refined by improvements in imaging, planning software and delivery systems. Newer modalities, such as brachytherapy and proton radiation therapy, are emerging as alternatives to conventional external beam radiation therapy, and will no doubt play a larger part in the treatment of localised prostate cancer in the near future.

Radiation therapy for localised prostate cancer

Localised prostate cancer can be subdivided into low, intermediate and high risk groupings. These risk groups enable the tailoring of treatments according to biochemical, pathological and clinical parameters. This, together with assessment of patient co-morbidities, life expectancy and patient preferences, enables the most appropriate treatments to be recommended to men with localised prostate cancer.

The National Comprehensive Cancer Network guidelines classify localised prostate cancer into four groups according to the risk of recurrence,¹ as follows (see table 1 for T stage definitions):

1. Low risk must have all of the following:

- stage T1-T2a
- Gleason score ≤ 6
- PSA ≤ 10 ng/ml

2. Intermediate risk must have any one of the following:

- T2b-T2c or
- Gleason score 7 or
- PSA 10.1–20 ng/ml

3. High risk must have any one of the following:

- stage \geq T3a or
- Gleason 8–10 or
- PSA > 20 ng/ml

4. Very high risk

- T3b or T4

Radiation therapy has an important role in the management of patients within all risk groups and has been a standard, curative treatment for prostate cancer for many decades.

Table 1: (AJCC TNM classification for prostate cancer)

TX	Primary tumour cannot be assessed
T0	No evidence of primary tumour
T1	Clinically inapparent tumour not palpable nor visible by imaging
T1a	Tumour incidental histologic finding in 5% or less of tissue resected
T1b	Tumour incidental histologic finding in more than 5% of tissue resected
T1c	Tumour identified by needle biopsy (eg. because of elevated PSA)
T2	Tumour confined within prostate
T2a	Tumour involves 50% or less of one lobe
T2b	Tumour involves more than 50% of one lobe but not both lobes
T2c	Tumour involves both lobes
T3	Tumour extends through the prostate capsule
T3a	Extracapsular extension (unilateral or bilateral)
T3b	Tumour invades seminal vesicle(s)
T4	Tumour is fixed or invades adjacent structures other than seminal vesicles - bladder neck, external sphincter, rectum, levator muscles and/or pelvic wall.

In recent years there has been increased interest and experience in more specialised forms of radiation therapy such as brachytherapy, along with significant refinements in the delivery of external beam photon radiation (image guidance, intensity modulated radiation therapy) and increasing use of particle therapy such as the application of protons.

Types of radiation therapy used to treat prostate cancer include:

- external beam radiation therapy (EBRT)
- high dose rate (HDR) brachytherapy

- low dose rate (LDR) brachytherapy/ or seed brachytherapy
- proton radiation therapy.

Low risk prostate cancer

In general, the curative treatment options available for low risk prostate cancer include:

- active surveillance – for a select group of low risk patients²
- surgery (radical prostatectomy)
- LDR brachytherapy
- external beam radiation therapy (EBRT) (including 3D conformal radiation therapy [3D-CRT] and intensity modulated radiation therapy [IMRT] techniques).

Less commonly used radiation treatment modalities include proton RT and stereotactic body RT.

RT for low risk prostate cancer in Australia takes two main forms – EBRT and LDR brachytherapy (always delivered with ¹²⁵I seeds in Australia). In the US and other countries where the facilities are available, proton radiotherapy and stereotactic RT are increasingly being used to treat low risk prostate cancers.

LDR (seed) brachytherapy

Low dose rate brachytherapy is a standard treatment option for patients with low risk disease, and for some patients with intermediate risk disease. Although no head-to-head randomised control trials have been completed comparing surgery to LDR brachytherapy (one noble attempt to do this failed to accrue patients – the Surgery Versus Internal Radiation in Treating Patients With Stage II Prostate Cancer [SPIRIT] trial),³ results from published series of patients treated with LDR brachytherapy have comparable outcomes to patients treated with radical prostatectomy.

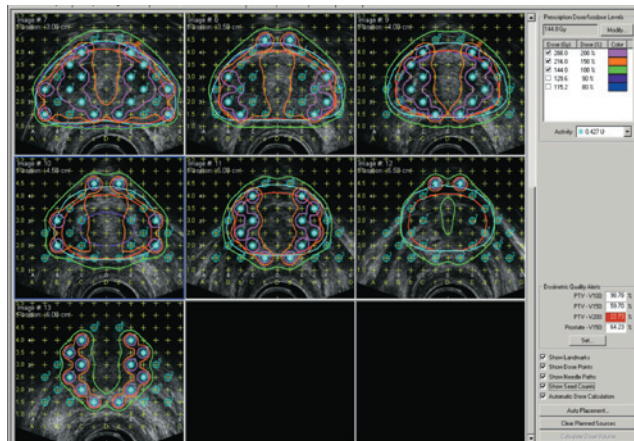
Series from large North American centres, such as the British Columbia Cancer Agency in Vancouver, Canada, the Seattle Prostate Institute in Seattle, US and the Memorial Sloan Kettering Cancer Centre in New York, US, indicate excellent biochemical outcomes are achievable with this form of radiation therapy, for example rates of biochemical relapse free survival of 95% at five years and 86% at 10 years.⁴⁻⁷

LDR brachytherapy allows escalation of the radiation dose to the prostate gland while delivering a lower dose to surrounding normal tissues, helping to minimise the risk of normal tissue injury to the rectum and bladder.

Patient selection for LDR brachytherapy is of great importance. Those with large prostates and significant lower urinary tract symptoms before treatment are more likely to suffer urinary problems after brachytherapy, and hence are less suitable for this form of treatment.

LDR brachytherapy involves the insertion of radioactive seeds directly into the prostate through the perineum under local, spinal or general anaesthetic using transrectal ultrasound guidance. Approximately 80-140 seeds (depending on the size of the prostate) are placed in the prostate using a standardised template and an individualised treatment plan (see figures 1, 2 and 3).

Figure 1 and 2: Pre-plan for ¹²⁵I LDR brachytherapy showing placement of seeds on axial ultrasound images taken during the planning volume study (including no. of seeds in each strand) and resultant dose distribution. The printouts are used to guide seed placement in the operating theatre.



Dept. ID:		Template: B & K Standard		Anisotropy: Factors (Point Model)	
Procedure Date: 21-Jul-2008		Prescription Dose: 144.0 Gy		Source Activity: 0.427 U [0.336 mCi]	
Total Activity: 58.072 U [45.726 mCi]					

Needle Number	Retraction (cm)	Hole Location	Number Seeds
1	0.50	c4.5	6
2	0.50	d4.5	6
3	0.00	C4.0	7
4	0.00	E4.0	7
5	0.00	b3.5	7
6	0.00	e3.5	7
7	0.50	B3.0	5
8	0.00	C3.0	7
9	0.00	E3.0	7
10	0.50	F3.0	5
11	1.00	a2.5	3
12	0.00	b2.5	7
13	0.00	e2.5	7
14	1.00	f2.5	3
15	0.50	B2.0	5
16	0.00	C2.0	7
17	0.00	E2.0	7
18	0.50	F2.0	5
19	1.00	a1.5	3
20	0.50	b1.5	4
21	0.00	e1.5	7
22	0.00	d1.5	7
23	0.50	e1.5	4
24	1.00	f1.5	3

Retraction Legend					
Plane 0	Plane 1	Plane 2	Plane 3	Plane 4	Special
0.00 cm	0.50 cm	1.00 cm	1.50 cm	2.00 cm	Other
○	△	□	◇	▽	○


Number of Needles	Seeds per needle
4	3
2	4
4	5
2	6
12	7

Plan Summary	
Total Activity [U]	58.07
Total Activity [mCi]	45.73
Total Needles	24
Total Seeds	136
Extra Seeds	
Total Seeds to Order	

Study Created by: _____
 Study Approved by: _____

VarSeed 7.1 (8/10/2005) FE16 0678 9E24 38DE E1D6C DEE45

Figure 3: Brachytherapy planning - seed positioning in 3D (red volume = prostate, blue volume = planning treatment volume). The planning treatment volume is usually the prostate with a margin of 4-5mm to encompass any areas of extracapsular tumour extension).



LDR brachytherapy is generally well tolerated with the main side-effects being acute and sub-acute irritative voiding symptoms. These usually settle within a few months as the radiation effect is largely limited to the first 6-10 months (the half-life of I^{125} is about two months).

EBRT

External beam radiation therapy for prostate cancer is usually given as a fractionated course of treatment with megavoltage photons delivered in daily treatments, five days a week for a period of seven to eight weeks.

Major advances in the planning and delivery of EBRT for prostate cancer have occurred in the past 5-10 years. These include:

- 3D conformal RT (3D-CRT)
- Intensity modulated radiation therapy (IMRT)
- Volumetric modulated arc therapy (VMAT)
- Image guided RT (eg. with the use of implanted fiducial markers, cone beam CT).

3D-CRT combines modern imaging (CT, MRI) with computerised planning to optimise prostate localisation, delineation and dose distribution. Complex shielding allows better conformation of the radiation dose to the treatment target, enabling tighter margins around the treatment volume and hence lower doses to surrounding normal tissues (see figure 4 and 5).

Figure 4: A 3D-CRT external beam radiation plan for treatment of prostate cancer, showing doses to the target (prostate – within the blue planning treatment volume) and normal tissues such as the rectum (outlined in brown), bladder (outlined in yellow) and femoral heads (outlined in pink and orange).

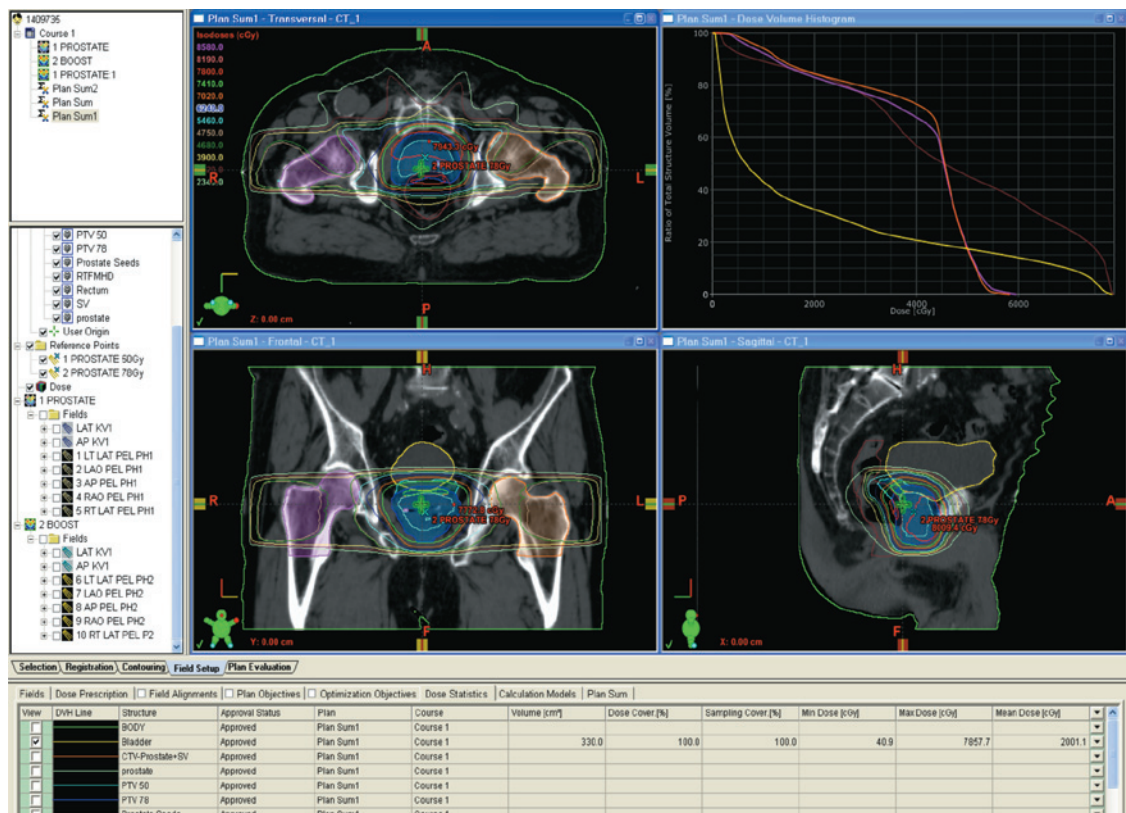
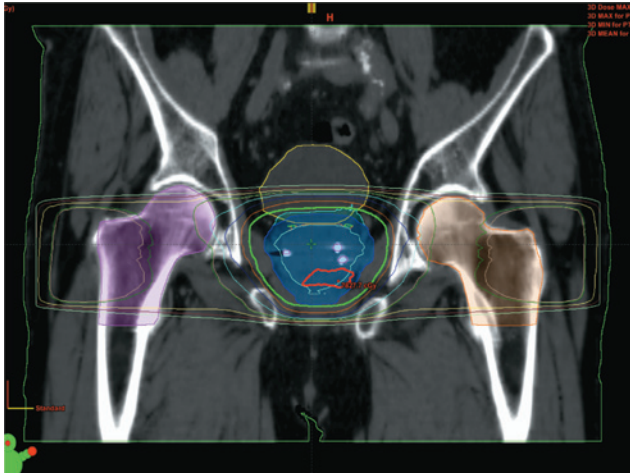


Figure 5: Coronal CT planning image showing three gold seed fiducial markers (in white) within the prostate.



IMRT is a form of 3D-CRT where the intensity of the radiation beam is adjusted throughout the course of treatment. By dividing the beam into multiple beamlets of non-uniform intensity, a more conformal dose distribution around irregular targets is enabled, with greater sparing of organs such as the rectum and bladder. This, in turn, can allow safer dose escalation to the target (ie. the prostate) to improve biochemical outcomes.^{8,9} IMRT can potentially be improved further by delivering the beam with a gantry that is moving rather than static. This technique is still in its early stages of development, however shows great promise in improving external beam radiation treatment of prostate cancer.¹⁰

Image guided radiation therapy (IGRT)

Improvements in imaging with CT, MRI and PET scanning have allowed better localisation of tumour volumes and more accurate treatment planning. This has been further enhanced by the ability to combine these different kinds of images.

IGRT is the use of daily imaging (for example with x-rays and/or CT) to track the location of the prostate and surrounding normal tissues during treatment. Commonly used methods include gold seed fiducial markers with daily portal x-rays, cone beam CT and ultrasound (see figure 6).

The main aim of image guidance is to improve treatment accuracy, enabling dose escalation and smaller treatment margins with lower doses to surrounding normal tissues. Long-term data is needed to determine the effects of image guidance and its consequent improvements in treatment accuracy on side-effects and cancer outcomes.

Proton radiation therapy

Protons are a form of particle RT, as opposed to conventional photon RT described above. The physical properties of protons mean that most of the radiation dose is deposited at the end of the particle track (called the Bragg peak), with rapid reduction in the radiation dose after this peak. This provides a sharp dose drop-off at the junction of the prostate with surrounding normal tissues such as the bladder and rectum.

Although proton therapy has been applied successfully to brain and spinal tumours for many years, it has only relatively recently begun to be used to treat prostate cancer. Long-term outcome data is limited and includes patients from multiple risk groups.¹¹

The main current drawbacks of proton RT are its cost, cost effectiveness and limited availability. It has also not been shown to be superior to current external beam treatment methods such as IMRT.

Stereotactic radiotherapy to the prostate

Stereotactic RT is another form of targeted RT that delivers higher doses per fraction (hypofractionation), to exploit the radiobiological properties of prostate cancers. This technology is still in its infancy with only limited early data published to date.¹² The larger fractional doses of such therapy do risk inducing higher rates of normal tissue complications, and reliable formal studies of the toxicity are yet to be published.

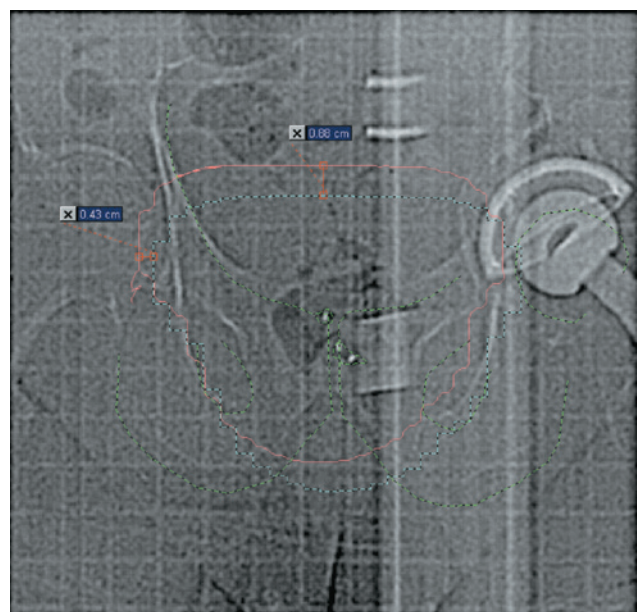
Intermediate and high risk prostate cancers

Curative treatment options include:

- Surgery (radical prostatectomy +/- lymph node dissection)
- EBRT
- HDR brachytherapy in combination with EBRT
- HDR monotherapy
- LDR (seed) brachytherapy with EBRT.

Hormone treatment is often used in combination with EBRT and HDR brachytherapy in these risk groups. Short durations of hormonal therapy (eg. six months) are favoured for patients with intermediate risk disease, whereas longer courses of hormonal therapy (eg. two to three years) are favoured for those with high risk disease.

Figure 6: Portal x-ray taken of a patient on treatment, showing matching of planned field and treatment fields using fiducial markers.



HDR brachytherapy with EBRT

Although there have been no randomised control trials to compare EBRT with or without HDR brachytherapy, the addition of HDR brachytherapy as a boost to a shorter course of EBRT has become commonplace. The advantages of HDR brachytherapy include a higher dose per fraction, and rapid reduction in dose outside of the prostate.

HDR brachytherapy is performed by placing catheters through the perineum into the prostate, under anaesthetic, with transrectal ultrasound image guidance. These catheters are placed positioned with a standardised template which is fixed to the perineum (see figures 7 and 8). Planning is based on a CT scan taken with the catheters in situ (see figure 9). Radioactive sources (for example, Ir¹⁹²) are introduced into the catheters for fixed periods using a remote afterloader unit (see figure 10).

Figure 7: Set-up for HDR brachytherapy including transrectal ultrasound probe within rectum and template for guidance.




Figure 8: Brachytherapy catheters in situ and template stitched to perineum.

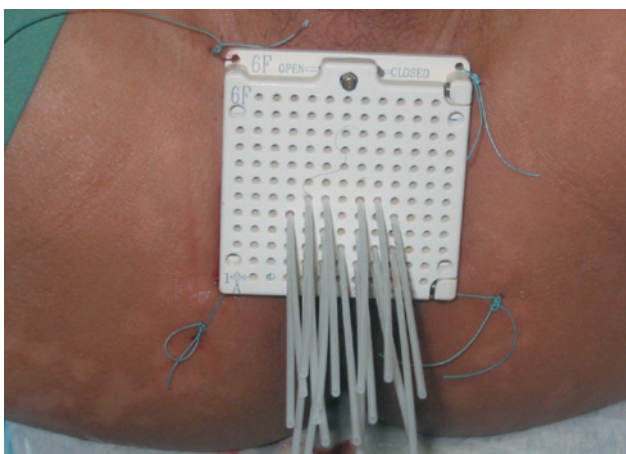


Figure 9: Axial CT image of HDR brachytherapy catheters in the prostate (bold red outline). The rectum is outlined in purple, the urethra in yellow. Note that urethra is spared the highest doses.

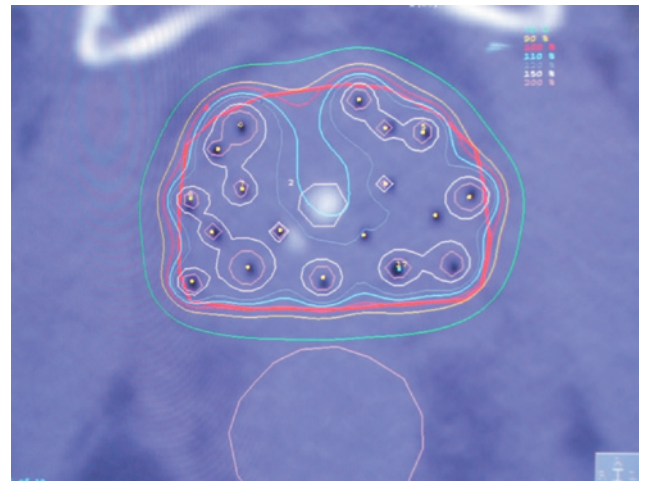
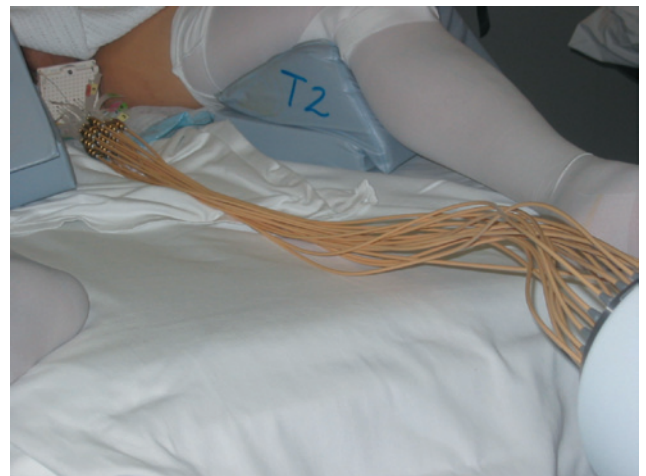

Figure 10: Catheters connected to remote afterloader on right (Ir¹⁹² source is within the afterloader and moves in and out via yellow tubes shown).



A recent review of the literature included patients in the low, intermediate and high risk groups treated with HDR brachytherapy.¹³ Rates of freedom from biochemical relapse for patients with intermediate risk disease were 88-100% at five years and 82-92% at 10 years; and for patients with high risk disease were 67-97% at five years, 62-74% at 10 years.

HDR monotherapy

HDR brachytherapy without the use of EBRT is increasingly being used to treat localised prostate cancer. However, the follow-up from such series is still short and further research is needed before this technique can be recommended for wider use.¹³

Post prostatectomy RT

External beam radiation therapy after radical prostatectomy is generally well tolerated and worthy of consideration

in several specific situations. It can be given either immediately following prostatectomy when the PSA is undetectable in the serum (adjuvant), or delayed until the biochemical failure when PSA becomes detectable in the serum (salvage).

The patients who might benefit from postoperative radiation therapy include those with:

- positive surgical margins
- evidence of extracapsular extension (pT3a)
- evidence of seminal vesicle involvement (pT3b)
- rising PSA post prostatectomy.

The advantages of adjuvant RT are that a lower total dose is required (60Gy) than for salvage radiation, and the possibility of increasing cure rates for men with positive margins or pT3 disease. Studies have shown significant improvements in freedom from biochemical relapse, metastasis-free survival, and long-term follow-up of one study showed better overall survival.^{14,15,16} However, adjuvant RT involves over-treatment of those whose cancer was destined never to recur even without further treatment.

Technologies such as 3D-CRT and IMRT, discussed above, can also be used to improve the delivery of radiation after prostatectomy.

Whether adjuvant RT or early salvage radiation therapy is superior, will be determined by the RAVES trial being conducted in Australia and New Zealand by the Trans Tasman Radiation Oncology Group, in collaboration with the Australian New Zealand Urogenital and Prostate Cancer Trials Group Ltd, and in the UK by the MRC-led Radiotherapy and Androgen Deprivation in Combination after Local Surgery (RADICALS) study.

Conclusion

Radiation therapy, in its many forms, has an important role to play in the management of localised prostate cancer. Recent advances in imaging, planning and delivery of radiation therapy are aimed at improving outcomes and reducing toxicity for treatment of prostate cancer. Ideally all prostate cancer patients should be referred to a radiation oncologist to further discuss their radiotherapy options and new developments in the field of RT and to facilitate the multidisciplinary management of this common malignancy.

References

1. National Comprehensive Cancer Network [Internet]. NCCN Clinical Practice Guidelines in Oncology: Prostate Cancer. Version 2; 2009 [cited 18 March 2009]. Available from: http://www.nccn.org/professionals/physician_gls/PDF/prostate.pdf.
2. Klotz, L. Active surveillance with selective delayed intervention for favourable risk prostate cancer. *Urol Oncol.* 2006;24(1):6-50.
3. Crook J, Wallace K, Jewett M, et al. Enhancing enrolment in difficult randomized trials: the profile of men accepting randomization to SPIRIT (surgical prostatectomy vs interstitial radiation). [Abstract] 2006 Prostate Cancer Symposium, February 24-26, 2006, San Francisco, CA. A-295, 2006.
4. Morris WJ, Keyes M, Palma D, Spadinger I, McKenzie MR, Agranovich A, et al. Population-based Study of Biochemical and Survival Outcomes After Permanent (125I) Brachytherapy for Low- and Intermediate-risk Prostate Cancer. *Urology.* 2009;73(4):860-65.
5. Sylvester, JE, Grimm, PD, Blasko, JC, Miller J, Orio P, Skoglund S, et al. 15-Year biochemical relapse free survival in clinical Stage T1-T3 prostate cancer following combined external beam radiotherapy and brachytherapy; Seattle experience. *Int J Radiat Oncol Biol Phys.* 2007;66(3): 57-67.
6. Zelefsky MJ, Kuban DA, Levy LB, Potters L, Beyer DC, Blasko JC, et al. Multi-institutional analysis of long-term outcome for stages T1-T2 prostate cancer treated with permanent seed implantation. *Int J Radiat Oncol Biol Phys.* 2007;67(2):327-33.
7. Shapiro EY, Rais-Bahrami S, Morgenstern C, Napolitano B, Richstone L, Potters L. Long-term outcomes in younger men following permanent prostate brachytherapy. *J Urol.* 2009; 181(4):1665-71.
8. Zelefsky MJ, Levin EJ, Hunt M, Yamada Y, Shippy AM, Jackson A, et al. Incidence of late rectal and urinary toxicities after three-dimensional conformal radiotherapy and intensity-modulated radiotherapy for localized prostate cancer. *Int J Radiat Oncol Biol Phys.* 2008; 7(4):1124-29.
9. Zelefsky MJ, Chan H, Hunt M, Yamada Y, Shippy AM, Amols H, et al. Long-term outcome of high dose intensity modulated radiation therapy for patients with clinically localized prostate cancer. *J Urol.* 2006;176(4 Pt 1):1415-9.
10. Palma D, Vollans E, James K, Nakano S, Moiseenko V, Shaffer R, et al. Volumetric Modulated Arc Therapy for Delivery of Prostate Radiotherapy: Comparison With Intensity-Modulated Radiotherapy and Three-Dimensional Conformal Radiotherapy. *Int J Radiat Oncol Biol Phys.* 2008;72(4):996-1001.
11. Slater JD, Rossi CJ Jr, Yonemoto LT, Bush DA, Jabola BR, Levy RP, et al. Proton therapy for prostate cancer: the initial Loma Linda University experience. *Int J Radiat Oncol Biol Phys* 2004;59(2):348-52.
12. King CR, Brooks JD, Gill H, Pawlicki T, Cotrutz C, Presti JC Jr. Stereotactic body radiotherapy for localized prostate cancer: Interim results of a prospective phase II clinical trial. *Int J Radiat Oncol Biol Phys.* 2009;73(4):1043-8.
13. Pisansky TM, Gold DG, Furutani KM, Macdonald OK, McLaren RH, Mynderse LA, et al. High-dose-rate brachytherapy in the curative treatment of patients with localized prostate cancer. *Mayo Clin Proc.* 2008;83(12):1364-1372.
14. Bolla M, van Poppel H, Collette L, van Cangh P, Vekemans K, Da Pozzo L, et al. Postoperative radiotherapy after radical prostatectomy: a randomised controlled trial (EORTC trial 22911). *Lancet.* 2005;366(9485):572-8.
15. Thompson IM Jr, Tangen CM, Paradelo J, Lucia S, Miller G, Troyer D, et al. Adjuvant radiotherapy for pathologically advanced prostate cancer: a randomized clinical trial. *JAMA.* 2006;296:2329-2335.
16. Wiegel T, Bottke D, Steiner U, Siegmann A, Golz R, Störkel S, et al. Phase III postoperative adjuvant radiotherapy after radical prostatectomy compared with radical prostatectomy alone in pT3 prostate cancer with postoperative undetectable prostate-specific antigen. *J Clin Oncol.* 2009;27(18):2924-30